

## Our Clinicians



### Dentistry, Oral & Maxillofacial Surgery

**Peter Southerden**  
BVSc MBA Dip.EVDC MRCVS  
RCVS Recognised & European  
Specialist in Veterinary Dentistry



### Dentistry, Oral & Maxillofacial Surgery

**Andrew Perry**  
BVSc MRCVS



### Soft Tissue Surgery

**Tim Charlesworth**

MA VetMB DSAS (ST) MRCVS  
RCVS Recognised Specialist in  
Small Animal Surgery (Soft Tissue)



### Orthopaedics

**Duncan Barnes**

MA VetMB DSAS (Orth) MRCVS  
RCVS Diplomate in Small Animal  
Surgery (Orthopaedics)



### Orthopaedics

**Andy Morris**

BSc (Hons) BVSc CertAVP(GSAS)  
MRCVS RCVS Recognised Advanced  
Practitioner in Small Animal Surgery



### Internal Medicine

**Paul Higgs**

MA VetMB CertSAM DipECVIM-CA  
MRCVS, RCVS Recognised and  
European Specialist in Small Animal  
Internal Medicine



### Internal Medicine

**Jenny Reeve**

BVSc DipECVIM-CA MRCVS  
RCVS Recognised and European Specialist  
in Small Animal Internal Medicine



### Ophthalmology

**Ida Gilbert**

BVSc CertVOphthal MRCVS  
RCVS Advanced Practitioner  
in Veterinary Ophthalmology



### Ophthalmology

**Mark Ames**

BVSc CertVOphthal CertVDI MRCVS  
RCVS Advanced Practitioner in  
Veterinary Ophthalmology



### Cardiology

**Andrew Francis**

BVSc Cert VC DipECVIM-CA (Cardiology)  
MRCVS RCVS Recognised & European  
Specialist in Cardiology



### Dermatology

**Natalie Barnard**

BVetMed CertVD DipECVD MRCVS  
European and RCVS Recognised  
Specialist in Veterinary Dermatology

## Veterinary Dermatology Referral Service Available from January 2018



**Natalie Barnard**, European and RCVS recognised specialist in Veterinary Dermatology will be joining our team on 18th January 2018. She enjoys all aspects of

dermatology in dogs and cats from a keen interest in allergic skin and ear diseases in small animals to more complicated immune mediated problems.

Natalie graduated from the Royal Veterinary College, London in 2001. She then worked in small animal practice for 2 years before returning to

the RVC in 2003 to undertake a 3 year residency in Veterinary Dermatology. Natalie attained her RCVS Certificate in Veterinary Dermatology in 2006 and was awarded her European Diploma in Veterinary Dermatology in 2009. Natalie has worked at Bristol University as the clinical lead in Dermatology for the last 8 years before joining the Eastcott Referrals team.

Natalie is able to perform a lot of in house diagnostic tests during appointments including skin scrapes, hair plucks, cytology, otoscopy and intradermal testing when appropriate.

*There is an opportunity to meet Natalie on Wednesday 22nd November 2017 for her free evening talk - The Approach to the Itchy Dog*

## Free Dermatology CPD Evening

**22<sup>ND</sup> NOVEMBER 2017**  
**APPROACH TO THE ITCHY DOG**  
*with Natalie Barnard*

Fed up with seeing itchy dogs, giving them steroids and never getting a diagnosis? Then this is the lecture for you.

We will discuss the logical approach to the itchy dog with practical tips on how to reach a diagnosis in these cases and manage client expectations.

This evening will be a good opportunity for vets to meet Natalie who will join the Referral Team in January 2018.

## Free Canine Nasal Disease CPD Evening

**6<sup>TH</sup> DECEMBER 2017**  
**THE DIAGNOSTIC APPROACH AND WORK UP OF SMALL ANIMAL NASAL DISEASE**

This free CPD evening for vets will be provided by our medicine specialists Paul Higgs and Jenny Reeve and will cover the approach to canine nasal disease (featuring both first opinion techniques and referral procedures), before working through some case examples.

CPD Courses run from 7.30pm - 9pm with refreshments from 7pm

*For more information or to book a place on one of our courses, please visit our website.*

# Traumatic Injuries to Juvenile Teeth

with Andrew Perry

The eruption of the secondary, or permanent, dentition occurs between 12 weeks and 28 weeks in dogs. The first teeth to erupt are the incisors and the last the molar teeth. On completion of eruption the crown of the tooth is fully formed and will not change for the remainder of the dog's life unless an external force is applied. This does not apply to the root of the tooth.

Once mature the tooth is essentially a hollow tube closed at both ends with perforations at the root tip to allow neuro-vascular tissue to enter which in combination with fibrous stroma and odontoblasts form the pulp tissues. Odontoblasts deposit dentin on the internal surface of the root progressively throughout life. This continued deposition can be used as a marker of pulpal vitality as asymmetry in root canal diameter between contralateral teeth, or unchanged diameter between the same tooth at different times indicates pathology.

At the time of eruption, the root of the tooth is immature. The root develops from the crown end towards the tip of the root but at the time of eruption the thickness of the dentin tapers from the crown rapidly to an egg shell thickness and the root tip is not formed. The root reaches its final, mature anatomy between 9 and 15 months of age, depending on the tooth.

The canine teeth and the maxillary 4th premolar and mandibular 1st molar teeth are considered to have strategic importance. The loss of these teeth has implications for an individual's long-

term quality of life and extraction is an invasive procedure and associated with significant potential complications. Of course, loss of teeth may be unavoidable and these patients will adapt, once recovered from treatment, but there may be options to preserve these teeth with appropriate action.

Fracture of teeth is common in dogs and can be broadly defined as either complicated, directly exposing the pulp, or uncomplicated involving the enamel and dentine only. Exposure of the pulpal tissues to the microflora of the oral cavity will result in bacterial colonisation of the pulp and its subsequent death. The root canal following plural necrosis is a privileged environment for these bacteria due to the inability for an effective immune response to be mounted. Eventually, the inflammatory mediators and bacteria will cause a peri-apical periodontitis which may progress to a true apical abscess, granuloma or radicular cyst. Uncomplicated fractures can also result in colonisation of the pulp by migration of bacteria along the exposed dentinal tubules. The closer the fracture to the pulp the greater the potential for pulpitis and therefore this is more common in younger patients as the dentin is less thick than older individuals. Following a complicated crown fracture, bacterial colonisation of the pulp is rapid and an irreversible pulpitis and subsequent pulp necrosis is likely to occur within 7 days from the time of pulp exposure.

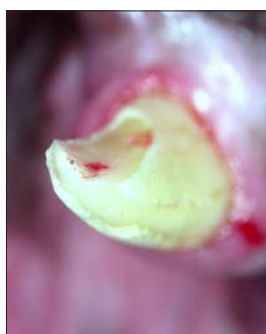Preservation of endodontically challenged teeth may be achieved through root canal treatment. The

success of root canal treatment is reliant on elimination of bacteria from and the subsequent sealing of the root canal. This is not possible if the root is not fully formed as in the case of immature teeth and thin dentinal walls of these immature teeth are unlikely to be able to stand the rigours of life.

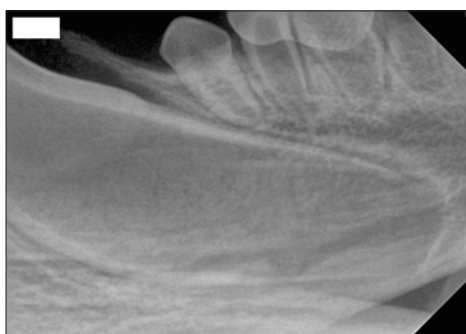
Preservation of immature teeth is reliant on the preservation of the vitality of the pulp to allow for continued maturation of the root. Success rates for the maintenance of pulp vitality is at its highest within 48 hours of pulp exposure and if treated appropriately 92% of teeth are reported to remain vital for the length of the patient's life. As a result, a complicated crown fracture of an immature tooth must be considered as an emergency.

The treatment used for preservation of immature fractured teeth is referred to as a Vital Pulp Therapy. This involves amputation of the most coronal part of the pulp and placement of dressing material directly onto the pulp and then restoration of the fracture to prevent ingress of bacteria. The dressing material allows dentin deposition at the cut surface of the pulp forming a dentinal bridge further sealing the pulp. Follow up dental radiographs are important to monitor the continued vitality of the tooth and these are routinely performed at 3 and 18 months after treatment.

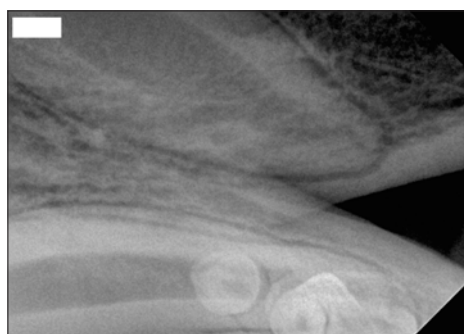*If you have an urgent case that you wish to discuss both Peter Southerden and Andrew Perry at Eastcott Referrals are happy to be contacted directly by telephone or email.*



Fractured tooth with pulp exposure.



Radiograph of immature tooth root, the root canal is extremely wide, the dentinal walls thin and there is no formed root apex.



The same tooth seen in Image 2 four months after treatment indicating continued development of the root.



## Prize Draw Winner

Congratulations to Katherine Love from St Vincents Vets, Wokingham, who won this quarter's prize. Katherine wins £200 in vouchers to spend at Great Fosters in Egham. The vouchers can be spent in The Tudor Rooms, the Michelin starred restaurant or put towards an overnight stay. Our draw takes place quarterly for referring vets. Names are added automatically each time a vet makes a referral.

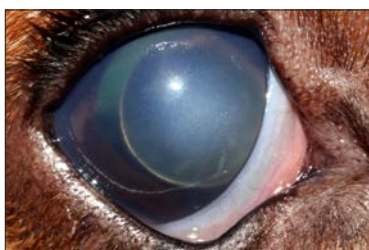
# Canine Anterior Lens Luxation

with Mark Ames

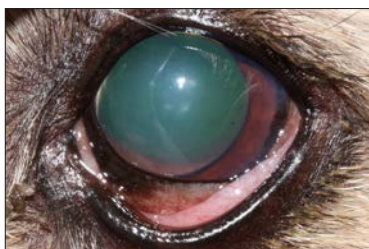
Anterior lens luxation (ALL) can occur as a result of a primary inherited weakness in the attachments of the lens or as a secondary consequence of another intraocular disease (e.g. uveitis, hyper mature cataract and glaucoma). Primary ALL is frequently seen in middle aged terrier breeds (especially the Jack Russell) and the Border Collie.

## Four cases of anterior lens luxation:

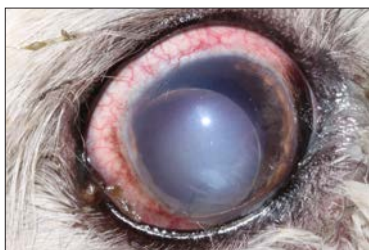The crystalline lens can be seen in the anterior chamber in front of the iris



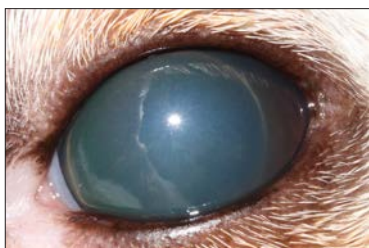
**Case 1.** ALL secondary to glaucoma in a Basset Hound FN 8yrs.



**Case 2.** Primary ALL in a Jack Russell Terrier MN 6yrs.



**Case 3.** ALL secondary to chronic uveitis in a Maltese Terrier FN 10 yrs.



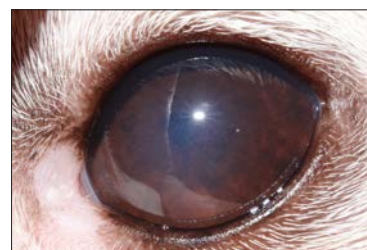**Case 4.** Primary ALL in a Jack Russell Terrier FN 4yrs.

## Diagnosis

It can sometimes be difficult to identify ALL with the naked eye. Clinical signs associated with ALL include a raised or erratic intraocular pressure, scleral injection, a focal corneal oedema (this is the result of the lens touching the corneal endothelium) and of course a lens in the anterior chamber. Taking a photograph (with flash) can be a great help as the edge of the lens will often be clearly highlighted. In cases of ALL the whole of the pupillary margin will not be clearly visible as it will be at least partially obscured by the lens. If it is still unclear or if dense corneal oedema makes visually identifying ALL impossible then an ultrasound examination can be very helpful.

## Treatment

Treatment options for ALL can be divided into the surgical removal of the lens or medical management following the reduction of the lens into the posterior chamber ('couching'). Surgical removal of the lens can be achieved via a large corneal incision and the extraction of the intact lens inside its capsule (intracapsular lens extraction (ICLE)) or via a small incision using phacoemulsification to break up the lens inside the eye before aspirating it in a similar fashion to cataract removal. 'Couching' involves applying careful pressure through the cornea in order to reduce the lens back behind the iris and then trapping it there by inducing miosis. 'Couching' has been recently studied and found to have comparable success rates to surgical intervention. The procedure can be performed under sedation or conscious in a co-operative patient. This is not a viable option if the lens has formed adhesions to the iris (synechiae) and may be less successful if ALL has been present for more than two weeks.



**Case 4:** following couching of the lens and medical therapy to induce miosis. The eye is comfortable and visual.

Untreated cases of ALL will very often progress to glaucoma and retinal detachment so effective treatment should be sought promptly. Unfortunately, the incidence of serious complications is high following both surgical and medical management of ALL. The genetic basis of primary ALL has been established in many breeds and it is hoped that this may lead to a reduction in the frequency of this problem. Primary ALL will almost always affect both eyes eventually. Following the diagnosis of ALL the fellow eye should be carefully monitored for any signs of lens instability. In the early stages of lens instability, the iris and/ or lens may be seen to subtly tremble as the eye moves. At this stage inducing miosis can be helpful by preventing the lens from moving into the anterior chamber.

## Summary

- Suspect ALL in any case of unexplained corneal oedema
- Terrier breeds especially the Jack Russell are most commonly effected
- ALL most commonly occurs between 3 and 7 years of age
- Treatment can be medical or surgical
- Closely monitor the fellow eye



# Rotating Internship Programme

We have just begun the second ever year of our rotating internship programme. This offers interns a high level of exposure to referral level cases in internal medicine, soft tissue surgery, orthopaedics, ophthalmology and dental and maxillofacial surgery. With the exception of the dental and oral surgery service we currently do not offer residency programmes. This means that our interns can receive a high degree of one-to-one training in referral cases, helping them to determine whether they wish to pursue further specialist training.

We have found the interns to be a valuable part of the service that we offer and our outgoing team have worked long and hard hours to support our 24-hour hospital care.

We are extremely grateful to our team for their diligence, care and stamina over the past year and we are very proud of their achievements during this time. Of this year's team, we have many success stories including Sarah Finnegan who will be going on to undertake a PhD in neurology at the Royal Veterinary College, Daniella who is now registered on an internal medicine residency in Italy and Malwina who has successfully presented an excellent research abstract at the British Association of Veterinary Ophthalmologists and hopes to go on to undertake a residency in ophthalmology.

We are also very pleased that Emma will be staying on at Eastcott Veterinary Hospital as part of our first opinion team whilst applying for neurology residencies.



**Sarah Finnegan** (left) will be undertaking a PhD in Neurology at Royal Veterinary College.

We are excited to welcome five new interns to our team; Dave, Francesco, Zuzannah, Sarah and Cristina who have all just undertaken our week-long induction programme. Their internship programme will run over a 12-month period.

Well done to all of our interns for completing their year with flying colours and a warm welcome to our new recruits.

We will be advertising for next year's programme in the Spring.

**Paul Higgs**

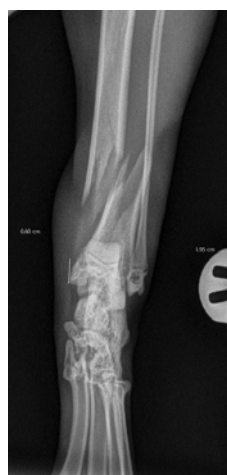*Head of Internal Medicine and Internship Coordinator*

## Locking Compression Plate (LCP) and the PAX Advanced Locking systems

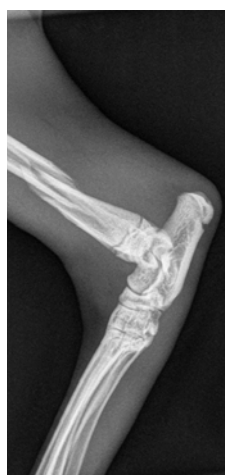*with Andy Morris*

Andy Morris was recently published in the JSAP on complication risks with cat tibial fracture repairs. Here he writes on the use of Locking Compression Plate (LCP) and the PAX Advanced Locking systems. Understanding the correct application of these plating systems allows the successful treatment of fractures that might otherwise have proved difficult or prone to failure.

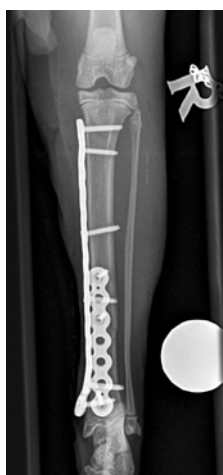These radiographs show a distal tibial fracture in a six-month cat. Multiple fissure lines can be seen extending towards the distal tibial physis. The tibia is a common site of non-union in the cat and plate failure by bending following tibial fracture stabilisation is reported. In this case, an orthogonal plate has been applied to the cranial aspect of the tibia. This not only allows increased construct stiffness in the sagittal plane but provides for an additional screw fixation point. This can be very useful with distal fractures.



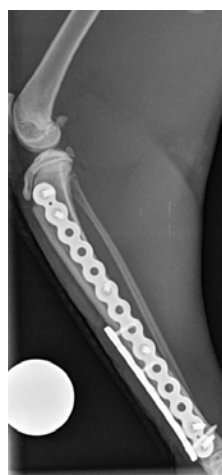Tarsus Cranio-caudal



Tarsus Lateral



Tibia Cranio-caudal



Tibia Lateromedial

The cat, in this case, was allowed early ambulation and went on to make a full recovery. The PAX advanced locking system is well suited to cat fracture repairs such as this.

### Eastcott Referrals

Eastcott Veterinary Hospital  
Edison Park, Dorcan Way, Swindon, Wiltshire SN3 3FR  
Tel: 01793 528341 Fax: 01793 401888

Email: [referrals@eastcottvets.co.uk](mailto:referrals@eastcottvets.co.uk)

[www.eastcottreferrals.co.uk](http://www.eastcottreferrals.co.uk)

### Opening Hours

Monday to Friday 7am - 8pm  
Saturday and Sunday 8.30am - 8pm

